

Protective Effects of Wheat Germ Oil on Doxorubicin-Induced Hepatotoxicity in Male Mice

Abdallah M. Sliai

Department of Biology, Faculty of Science
Taif University, Taif, KSA
amst60@hotmail.com

Abstract: *The present study aimed to investigate the possible protective role of the wheat germ oil as a natural antioxidant on doxorubicin –induced liver toxicity. Studies were performed on four groups of mice: Control group, wheat germ oil group (100 mg/kg b.w.), Doxorubicin group (2.5 mg/kg/day) for seven days, and doxorubicin plus wheat germ oil group. Histopathological examination of liver sections showed that doxorubicin caused destructed hepatic cords, hepatocytes degeneration, necrotic areas, vacuolation and widening of the blood sinusoids. Immunohistochemical localization of Caspase-3 for apoptosis was performed. Doxorubicin treated animals showed positive reaction to Caspase 3 in hepatocytes as compared with controls. Administration of wheat germ oil plus doxorubicin showed reduction in caspase 3 immunoreactivity and apoptosis induced by doxorubicin.*

Keywords: *Doxorubicin, wheat germ oil, histopathology, liver, mice*

1. INTRODUCTION

Doxorubicin is one of the most widely used anti-cancer drugs. The use of doxorubicin has been limited largely due to possible diverse cardiac, renal, hematological and testicular toxicities (Gillick, et al., 2002). Adriamycin can have serious side effects in liver (Saad, et al., (2001). Doxorubicin causes an imbalance between free oxygen radicals (ROS) and antioxidants. The disturbance in oxidant - antioxidant systems results in tissue injury that is demonstrated with lipid peroxidation and protein oxidation in tissue (Karaman et al., 2006). It has been shown that free radicals are involved in doxorubicin-induced toxicities (Yagmurca et al., 2006). The chemical structure of doxorubicin causes the generation of free radicals and the induction of oxidative stress that correlates with cellular injury (Saad et al., 2001)). It has been demonstrated that the development of doxorubicin cardiomyopathy involves apoptosis of cardiomyocytes , myocardial dysfunction in heart failure (Takemura and Fujiwara, 2007).

Apoptosis (programmed death) happens as a result of organism aging, or due to exposed to toxins in which mitochondria, endoplasmic reticulum with a lack of typical necrotic signs. It is known that adriamycin, antineoplastic antibiotic cause apoptotic death in hepatocytes of adult rats (Pedrycz et al., 2004). Free radicals scavengers are known to reduce adriamycin-induced toxic effects. Wheat germ is the component of wheat kernel with the highest nutritional value (Zhu et al., 2006). Wheat germ oil also contains alpha- and gamma- tocotrienols (Leenhardt et al., 2008; Hassanein and Abedel-Razek, 2009) and fatty acids which has anti-inflammatory effect, decreases O₂- production and NADPH oxidase activity ,and thereby, has antioxidant activity (Alessandri et al.,2011). It is known that the phenolic compounds found in this oil also have antioxidant effect (Niu et al., 2011). Wheat germ oil compensated the imbalance of the serum biochemical factors in the rats to make it as the control level (Megahed, 2011).

The aim of this experiment was to investigate the potential hepatoprotective effects of wheat germ oil on the livers of mice treated with doxorubicin.

2. MATERIALS AND METHODS

2.1. Animals and Experimental Design

Sexually mature male Swiss albino mice weighing 35 ± 5 g were used. The animals were housed in cages, fed a standard laboratory diet and water *ad libitum*. The animals were exposed to a 12 h

light/dark cycle at a room temperature and left to acclimatize for one week before the experiments. Mice were divided into four groups, six for each:

Group I (control group): treated with saline for seven days orally.

Group II (wheat germ oil group): received orally oil (100 mg/kg b.w).

Group III (Doxorubicin group): doxorubicin was injected intraperitoneally (2.5 mg/kg/day), for consecutive seven days.

Group IV (Doxorubicin plus wheat germ oil group): received doxorubicin intraperitoneally (2.5 mg/kg/day), for consecutive seven days plus wheat germ oil (100 mg/kg b.w).

2.2. Histopathological Examinations

At the end of the experiment, animals from each group were killed by cervical dislocation. Liver from animals was carefully separated and cut into small pieces. Tissue immediately fixed in 10% neutral buffered formalin for histopathological and immunohistochemical studies. Samples were dehydrated in ascending grades of ethanol, cleared in xylene and embedded in paraffin. Sections (6 μ m thickness) were cut and stained with hematoxylin and eosin.

2.3. Immunohistochemistry

For the detection of caspase-3 protein, immunohistochemical staining was performed. Slides were deparaffinized, dehydrated, washed in phosphate buffer saline then covered with peroxide block staining and incubated at room temperature in humidity chamber for 10 min. Monoclonal caspase-3 antibody was applied on the tissue sections then incubated horizontally in humidity chamber for an hour, at room temperature. After removal of excess buffer, the sections were incubated in preformed strept avidin peroxidase. DAB substrate-chromogen (3,3-Diaminobenzidine tetrahydrochloride) was applied on slides for 5-15 min until the desired brown colour was obtained. Sections were counterstained Mayer's hematoxylin.

3. RESULTS

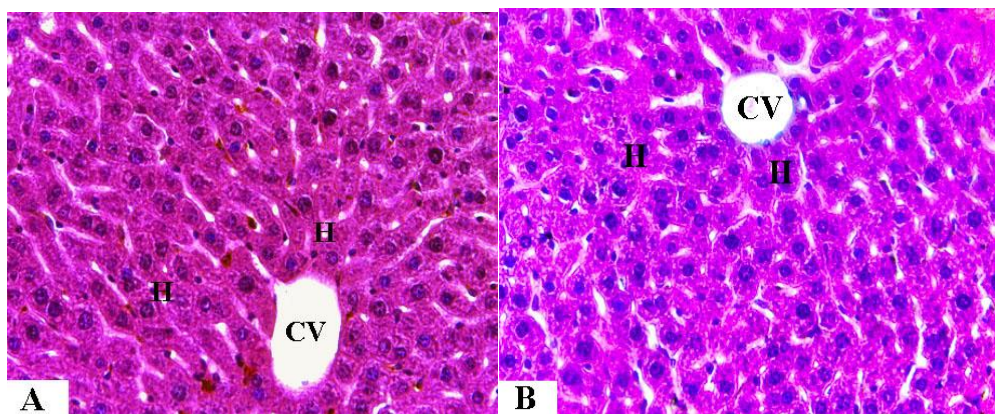
3.1. Histopathological Examination

Light microscopic examination of liver sections of control and wheat germ oil treated mice revealed that the hepatic lobules appeared to be formed of hepatocytes which arranged in cords radiating from the central veins. The hepatic sinusoids are in narrow spaces in between the hepatic cords (Figs. 1, 2). Doxorubicin treated mice shows pathological changes, destructed hepatic cords, destroyed cells forming degeneration areas, necrotic areas and vacuolation. Widening of the blood sinusoids also were seen.

3.2. Immunohistochemical Observations (Fig. 2)

Expression of Hepatic Tissue Caspase-3 (Apoptotic Index)

In this study, apoptotic immunopositive reactions in the liver were investigated with caspase-3. The expression of hepatic caspase-3 was weak of hepatocytes in control and wheat germ oil treated animals (Figs. 2A & 2B). The expression of caspase-3 was positive in hepatocytes in case of doxorubicin treated animals as compared with controls (Fig. 2C) Doxorubicin plus wheat germ oil treated animals showed less reaction to Caspase3 immunoreactivity (Fig. 2D).



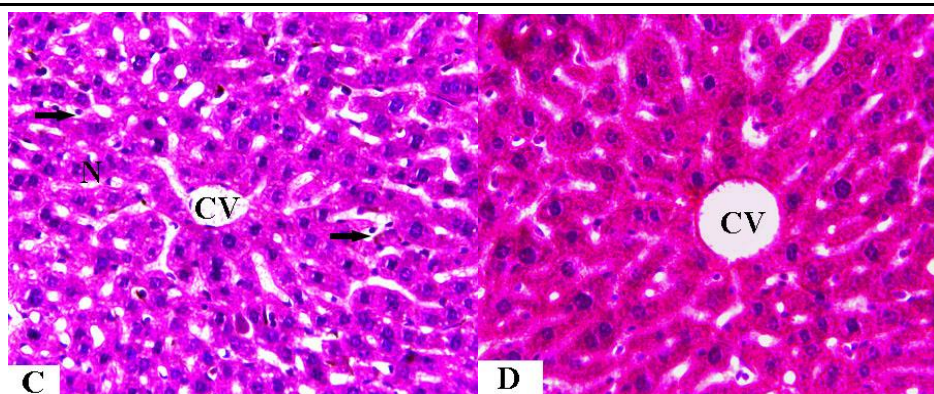


Fig1.

Fig(1A&B). A photomicrograph of a section in the liver of the control mice(A) and wheat germ oil treated mice (B) showing normal arranged hepatic cords and hepatocytes (H) around the central vein (CV) and blood sinusoids(S) (H&E , X 400).

Fig (1C). A photomicrograph of a section in the liver of doxorubicin treated mice showing degenerated hepatocytes, dilated blood sinusoids. Vacuolation (arrows), necrotic areas, (N). (H&E, X 400).

Fig (1D). A photomicrograph of a section in the liver of doxorubicin plus germ oil treated mice showing improvement of the histological structure. (H&E, X 400).

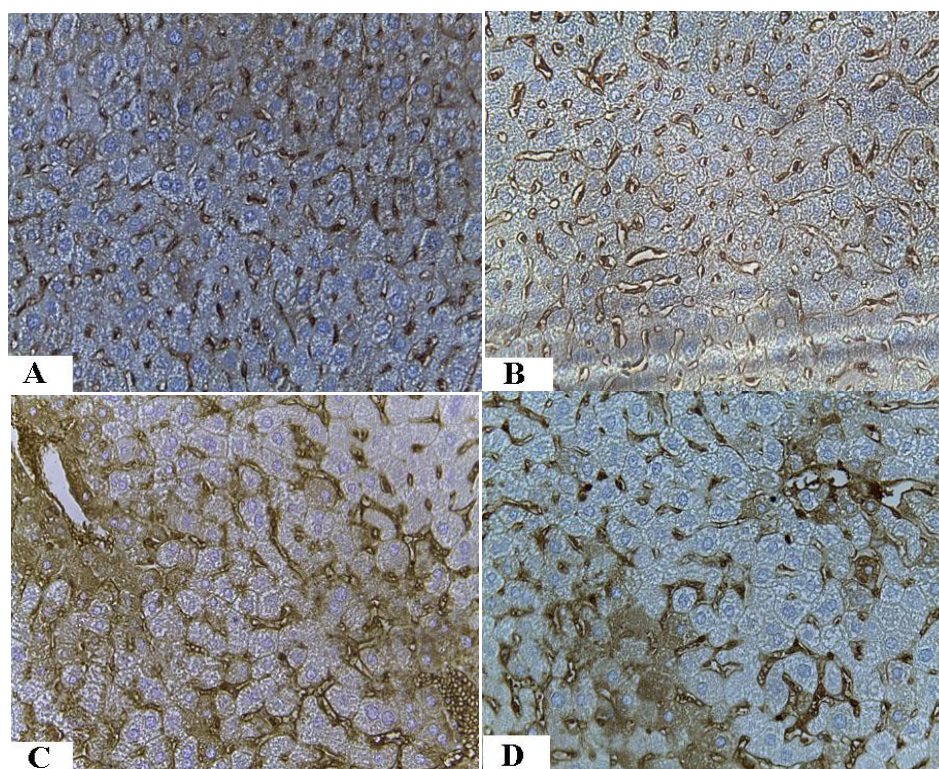


Fig2.

Fig (2A&B). Photomicrographs of a section of the liver of control and wheat germ oil treated mice showing negative immunoreactivity to caspase3. (X, 400)

Fig (2C). Photomicrograph of a section of the liver doxorubicin treated group showing strong positive immunoreactions of hepatocytes for caspase3. (X, 400)

Fig (2D). Photomicrograph of a section of the liver of doxorubicin plus wheat germ oil showing moderate immunoreaction for caspase3 of hepatocytes (X, 400)

Table2. Semiquantitative analysis of caspase-3 Immunostaining density in the liver.

	Control	Germ oil	Doxorubicin	Doxorubicin &wheat germ oil
(Caspase-3)	+	+	+++	++

Caspase-3 reactivity was estimated as follows: weak: + , moderate: ++, strong: +++.

4. DISCUSSION

Liver is the main site of doxorubicin metabolism. It is known that doxorubicin produce reactive oxygen species and reactive intermediates in liver resulting in oxidative stress followed by cell death. (Patel et al., 2010). The dose of doxorubicin used in this study corresponds to the dose that currently being used in clinical practice. (Chabner et al., 2001). In the present study, the histological examination of control mice showed normal architecture when viewed under the microscope. Doxorubicin treatment induced liver histopathological changes including marked disruption of hepatic cords, hepatocytes degeneration, dilated blood sinusoids, necrosis and vacuolation. The present results is in agreement with the research of (El-Sayyad et al., 2009). The present data indicated that doxorubicin induced liver damage by a possible oxidative injury. This is in agreement with several reports. Kalender et al., 2005) found that administration of doxorubicin (5 mg/kg/week for 6 weeks) caused liver damage. One of the most obvious hepatic damage resulting from doxorubicin administration is the ability of the drug to produce free radicals and reduce the antioxidant defense mechanism. The findings of the present study confirm the reports of (Deepa and Varalakshmi, 2003). It was shown that oral administration of wheat germ oil efficiently saturated the body with vitamin E and led to inhibition of peroxidation in rats (Paranich et al., 2000). Apoptosis is an important mechanism regulating cell number and their development in different organs and tissues, as well as in removing harmful and useless cells from the body (Francesch, 1986). Caspase-3 is a key mediator of apoptosis in mammalian cells the effector (Salvesen and Dixit, 1997). In this study, apoptotic index was increased in hepatocytes of doxorubicin treated animals, while decreased in hepatocytes of doxorubicin treated plus wheat germ oil treated animals. In the present findings, the hepatotoxic pathological effect of doxorubicin was ameliorated when treatment was combined with wheat germ oil. Thus, wheat germ oil appears to play a role in the attenuation of hepatic injury when exposed to doxorubicin.

REFERENCES

- Alessandri, J.M., Extier, A., AlGubory, K.H., Harbeby, E., Lallemand, M.S., Linard, A., Lavielle, M., Guesnet, P Influence of gender on DHA synthesis: The response of rat liver to low dietary α -linolenic acid evidences higher ω 3 D4- desaturation index in females, *Eur. J. Nutr.* doi ., 2011; 10.1007/s00394-011-0208-1.
- Chabner BA, Ryan DP, Paz-Ares L, Garcia-Carbonero R, Calabresi P. Antineoplastic Agents (Chapter 52). In Goodman and Gilman's the Pharmacological Basis of Therapeutics, Hardman JG, Limbird LE, Gilman AG, 10th ed., McGraw-Hill, New York, NY, USA, 2001: 1389–459.
- Deepa PR, Varalakshmi P. Protective effect of low molecular weight heparin on oxidative injury and cellular abnormalities in adriamycin induced cardiac and hepatic toxicity. *Chem Biol Interact* 2003; 146: 201e210.
- El-Sayyad HI, Ismail MF, Shalaby FM, Abou-El- Magd RF, Gaur RL, Fernando A, Raj MH, Ouhtit A Histopathological effects of cisplatin, doxorubicin and 5-fluorouracil (5-FU) on the liver of male albino rats. *Int J Biol Sci.* 2009;5(5):466-73.
- Franceschi C, Cell proliferation, cell death and aging. *Aging* , 1989;1: 3-15.
- Gillick J, Giles S, Bannigan J, Puri P Cell death in the early adriamycin rat model. *Pediatr Surg Int*; .2002, 18:576–80.
- Hassanein, M.M., Abedel-Razek, A.G. Chromatographic quantitation of some bioactive minor components in oils of wheat germ and grape seeds produced as by-products. *J. Oleo Sci* (2009) ; 58, 227–233
- Kalender Y, Yel M, Kalender S. Doxorubicin hepatotoxicity and hepatic free radical metabolism in rats. The effects of vitamin E and catechin. *Toxicology* 2005; 209:39e45
- Karaman A, Fadillioglu E, Turkmen E, Tas E, Yilmaz Z. Protective effects of leflunomide against ischemia reperfusion injury of the rat liver. *Pediatr Surg Int.* 2006; 22:428-434
- Leenhardt, F., Fardet, A., Lyan, B., Gueux, E., Rock, E., Mazur, A., Chanliaud, E., Demigne´ , C., Re´me´ sy, C. Wheat germ supplementation of a low vitamin E diet in rats affords effective antioxidant protection in tissues. *J. Am. Coll. Nutr.* 2008; 27, 222–22
- Megahed, M.G., Study on stability of wheat germ oil and lipase activity of wheat germ during periodical storage. *Agriculture and biology J. of North America.*, 2011; (1): 63-168.

- Niu, L.Y., Jiang, S.T., Pan, L.J. Preparation and evaluation of antioxidant activities of peptides obtained from defatted wheat germ by fermentation. *J. Food Sci. Technol.* doi: 2011; 10.1007/s13197-011-0318-z.
- Paranich V.A., Cherevko O.I., Frolova N.A., Paranich A.V., The effect of wheat germ oil on the antioxidant system of animals. *Lik. Sprava.*, 2000, 2, 40–44.
- Patel N, Joseph C, Corcoran GB, Ray SD .Silymarin modulates doxorubicin-induced oxidative stress, BclxL and p53 expression while preventing apoptotic and necrotic cell death in the liver. *Toxicol Appl Pharmacol.* 2010; 245(2):143-52.
- Pedrycz A., Wieczorski M., Czerny K . Increased apoptosis in the adult rat liver after a single dose of adriamycin administration. *Annales UMCS Sect D*, 2004; 59, 313-318.
- Saad SY, Najja TA, Al-Rikabi AC. he preventive role of deferoxamine against acute doxorubicin induced cardiac, renal and hepatic toxicity in rats. *Pharmacol Res.* 2001; 43: 211-8.
- Salvesen GS, Dixit V. Caspases: intracellular signaling by proteolysis. *Cell* 1997; 91: 443-446.
- Takemura, G., Fujiwara, H. Doxorubicin-induced cardiomyopathy from the cardiotoxic mechanisms to management. *Prog. Cardiovasc. Dis.* 2007; 49, 330–352.
- Yagmurca M, Erdogan H, Iraz M, Songur A, Ucar M, Fadillioglu E. Caffeic acid phenethyl ester as a protective agent against doxorubicin nephrotoxicity in rats. *Clin Chim Acta* , 2004; 348:27-34
- Zhu, K.; Zhou, H. M. and Qian, H. F. Proteins extracted from defatted wheat germ, nutritional and structural properties. *Cereal Chem.*, (2006; 83: 69–75).

AUTHOR'S BIOGRAPHY



Abdallah M. S. Sliai, Prof in Genecology, Faculty of Science, Taif University, Kingdom of Saudi Arabia

Sliai AM and GH Abdel-Rahman, 2014. Protection by wheat germ oil against doxorubicininduced

pathological changes and apoptosis in the kidney of male mice. *Res. Opin. Anim. Vet. Sci.*, 4(12): 695-700.

Abdel-Rahman GH, AM Sliai and MS Al-Harbi, 2014. Renal toxicity in the adult male mice exposed to methyle parathion and protective role of lycopene. *Res. Opin. Anim. Vet. Sci.*, 4(12): 701-706.

Abdallah M. Sliai1, Sayed A. M. Amer1,2 Molecular Relationships among Different Seryian Aegilops Species (Poaceae) *Natural Resources*, 2013, 4, 76-81

Hussein F. Farrag, Abdallah M. Sliai and Tha'ar F. Mhmas Allelopathic potentiality of two Heliotropium species on germination and protein expression of some plants *International Research Journal of Biotechnology* (ISSN: 2141-5153) Vol. 4(3) pp. 47-60, March, 2013

Abdallah Mahmoud Sliai1 and Sayed Amin Mohamed Amer1,2*Contribution of chloroplast DNA in the biodiversity of some Aegilops species *African Journal of Biotechnology* Vol. 10(12), pp. 2212-2215, 21 March, 2011.