

Advanced Techniques for Detection of Filariasis - A Review

Gurjeet Singh^{*1}, Raksha², A.D. Urhekar³

^{*1,2,3} Department of Microbiology, MGM Medical College and Hospital,
Sector-18, Kamothe, Navi Mumbai-410209, Maharashtra, India.
gurjeetsingh360@gmail.com

Abstract: *Filariasis is the disease which is caused by a group of filarial worms. They cause high morbidity and mortality among humans. The proper management is needed for preventing the morbidity and mortality by laboratory diagnostic methods. In past the blood smear was only the choice for detection of filarial worms, but now a days many recent techniques like Ultrasonography, PCR, ELISA, Membrane Filtration method for Microfilaria detection, and Binax Now® Filariasis Immunochromatographic Test (ICT) (a rapid test) are available for the diagnosis of filarial worms.*

Keywords: Diagnosis, PCR, ELISA, microfilaria.

1. INTRODUCTION

The filarial parasites are a group of arthropod worms and they settle in the subcutaneous tissue, deep connective tissue and lymphatic system of human beings. Lymphatic filariasis is caused by *Wuchereria bancrofti*, *Brugia malayi* and *B. timori*; and brugian filariasis accounts for about 13 million cases of the estimated 119 million worldwide cases of active infection and chronic diseases. The disease is undergoing a process of elimination through a WHO initiated global programme; and is at various phases in different countries. ¹ Infection with *B. malayi* is limited to Asia (China, India, and Malaysia), where it may coexist with *W. bancrofti*. *B. malayi* is a zoonosis, with feline and primate reservoirs, affecting about 20 million peoples. *B. timori* infection is limited to the islands of southeastern Indonesia. No animal reservoir is known for *B. timori* or *W. bancrofti*. Currently, one-third of the people infected with lymphatic filariasis live in India. ² Endemic areas has majority of affected subjects show a clinically asymptomatic infection and harbour microfilaria in their peripheral blood. It is important to know that even at this stage of the disease abnormalities of the lymphatic vessels such as dilatation appear to be irreversible even after treatment. ³

The most practical and feasible method of transmission interruption is rapid reduction of microfilarial load in the community by annual mass drug administration (MDA) of antifilarial drugs like DEC and albendazole. Based on this principle, the global programme to eliminate LF (GPELF) was developed. ⁴

2. RECENT ADVANCES IN DIAGNOSIS

The recent advances for the diagnosis of filariasis are mentioned here under:

2.1 Membrane filtration method for microfilaria detection

5 mL of venous blood collected in EDTA anticoagulant tube at night (between 11 pm and 1 am) in order to test the presence of circulating microfilaria and the collected blood filtered through millipore membrane filters (pore size 0.22). It enables an easy detection of microfilaria and quantifies the load of infection. They are usually observed in the early stages of the disease before clinical manifestations develop. Once the lymphoedema develops, microfilaria disappear from peripheral-blood. ⁶

2.2 Test for live adult worm

Ultrasonography has helped to locate and visualise the movements of living adult filarial worms of *W. bancrofti* in the scrotal lymphatics of asymptomatic males with microfilaraemia. The constant thrashing movement of the adult worms in their 'nests' in the scrotal lymphatics is

described as the ‘filaria dance sign’.⁷ The lymphatic vessels lodging the parasite are dilated and this dilation is not seen to revert to normal even after the worms are killed by diethylcarbamazine administration. Ultrasonography is not useful in patients with filarial lymphoedema because living adult worms are generally not present at this stage of the disease. Similarly ultrasonography has not helped in locating the adult worms of *B. malayi* in the scrotal lymphatics since they do not involve the genitalia.⁸ Ultrasonography of the scrotal area using a 7.5 MHz probe in real-time B mode to visualise the live adult worm and identify their characteristic movements in lymphatic vessels, i.e., the filariae dance sign (FDS), both sides of the scrotum (root of the scrotum, epididymis, spermatic cord, testis and the adjoining area), inguinal, popliteal, axillary and epitrochlear lymph nodes.^{9,10,12,15}

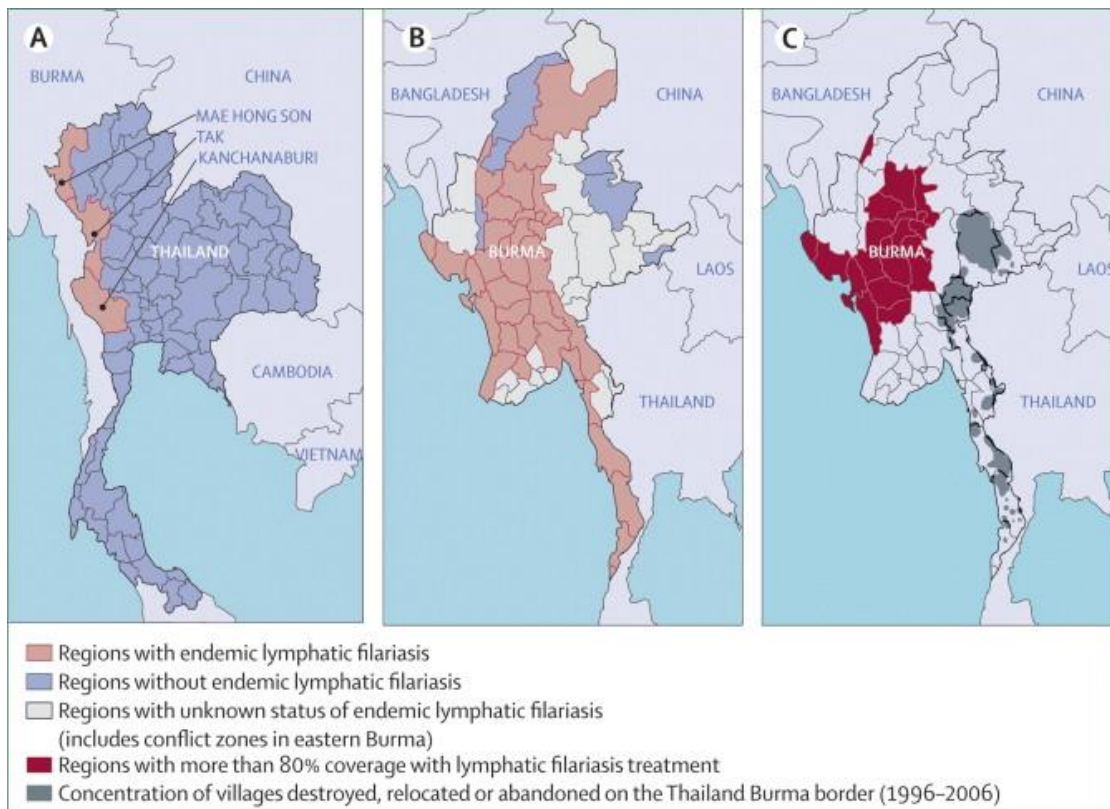


Fig.1: Shows countries with endemic and without endemic filariasis

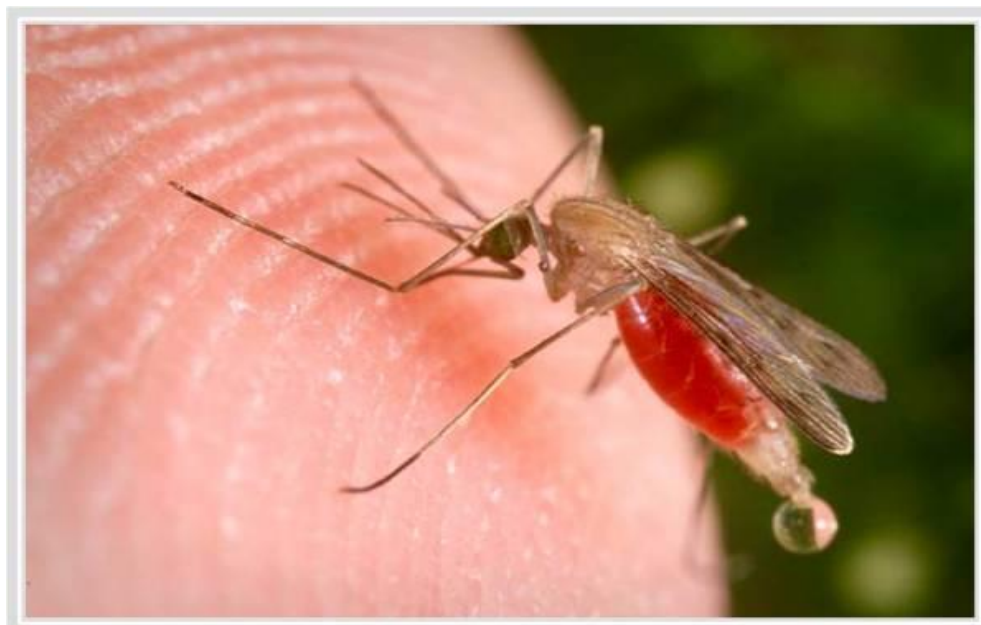

Fig.2: Mosquito Vector responsible for transfer the filarial infection

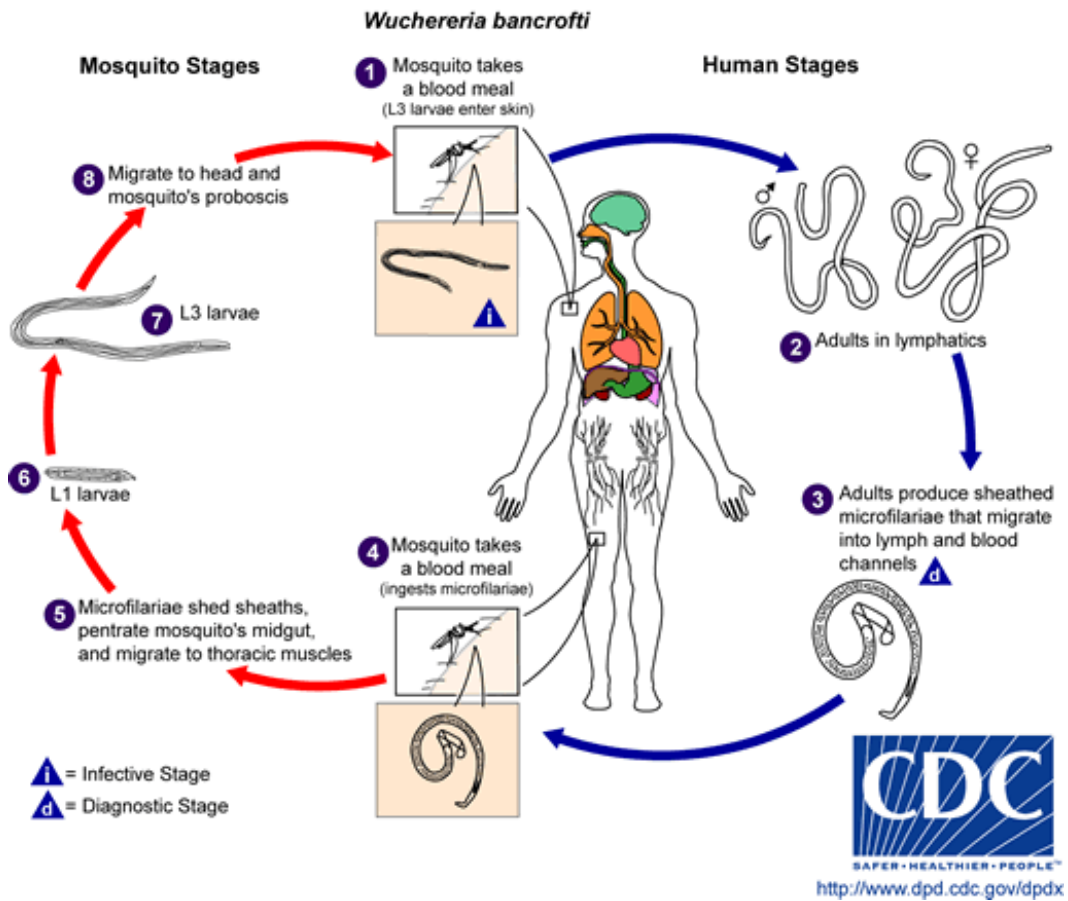


Fig.3: Life cycle of lymphatic filariasis in human and mosquito

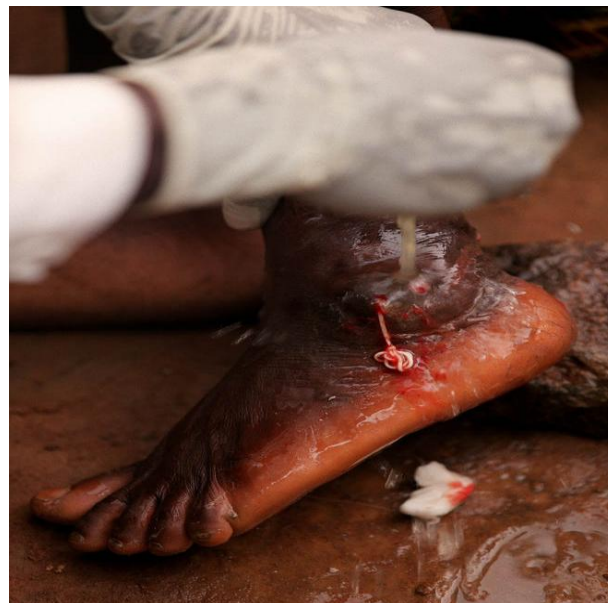

Fig.4: Shows removal of filarial worms from foot

2.3 Lymphoscintigraphy

The structure and function of the lymphatics of the involved limbs can be assessed by lymphoscintigraphy after injecting radiolabelled albumin or dextran in the web space of the toes, the structural changes are imaged using a gamma camera. Lymphatic dilatation, dermal back flow and obstruction can be directly demonstrated in the oedematous limbs by this method. Lymphoscintigraphy has shown that even in the early, clinically asymptomatic stage of the disease, lymphatic abnormalities in the affected limbs of people harboring microfilaria may occur.

2.4 Binax Now® Filariasis test

This test based on the principle of immunochromatography test. Binax Now® Filariasis test ICT card test has been shown to be a useful and sensitive tool for the detection of *Wuchereria bancrofti* antigen and is being used widely by lymphatic filariasis elimination programs to collect 100µl blood by finger prick using a calibrated capillary tube or measure 100µl of blood from a microcentrifuge tube using a micropipettor. Blood sample is to be added slowly to the white portion of the sample pad and wait for 10 minutes then the results to be read in 10 minutes otherwise false positive results will be obtained. The test was considered positive when both lines (test and control) could be read through the visualisation window. Any line (light or dark) appearing in the test position indicates that the result of the test is positive; it is negative when the control line can be seen.^{11,12}

2.5 ELISA test

Enzyme-linked immunosorbent assays (ELISA) in this test soluble extracts of microfilaria and infective larva or adult worms can be used for diagnosis. Positive readings were obtained in 93-100% of subjects living in endemic areas, those with microfilaraemia as well as those with clinical evidence of filariasis.¹³ Antigen testing is now recognized as the method of choice for detection of *W. bancrofti* infections. Unlike tests that detect microfilariae, antigen tests can be performed with blood collected during the day or night. However, existing enzyme-linked immunosorbent assay (ELISA) tests for filarial antigenemia are difficult to perform in the field, and this has limited their use in endemic countries.¹⁴ Highly sensitive and specific filarial antigen detection assays ELISA based format are now available for the diagnosis of *W. bancrofti* infection. This test is positive in early stages of the disease when the adult worms are alive and it becomes negative when the parasites are dead.¹⁴

2.6 Polymerase Chain Reaction (PCR)

The technique PCR-based assays are to introduced for the diagnosis of filariasis in the diagnostic reference laboratories. The PCR are now increasingly widespread in the developing countries. In recent years, real-time PCR has increasingly replaced conventional PCR (C-PCR) for technical reasons (improved sensitivity) and practical reasons (faster results with less labor). In addition, real-time PCR assays have the potential to be used as high-throughput diagnostic tools for the screening of blood donors, for epidemiological studies, or for the monitoring of control programs.⁵ These tests are of high specificity and sensitivity, and are able to detect parasite DNA in humans as well as vectors in both bancroftian and brugian filariasis. DNA probes used for detection of infection of the filariasis in vector/man^{6,16-19}

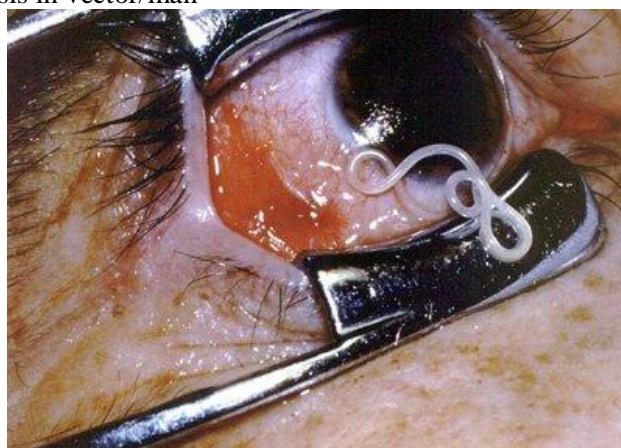


Fig. 5: Shows *Loa loa* adult worm in eye (eye worm)

3. CONVENTIONAL METHOD OF DIAGNOSIS

3.1 Demonstration of microfilarae in the peripheral blood

2-3 drops of blood are to be taken by finger prick method on a glass slide and a oval shaped thick smear is to be made with the help of corner of other slide and it is to be dried, then stained with Giemsa stain and is to be seen under the oil immersion lens by putting one drop of oil (100X), the morphology of the parasites are to be recorded.

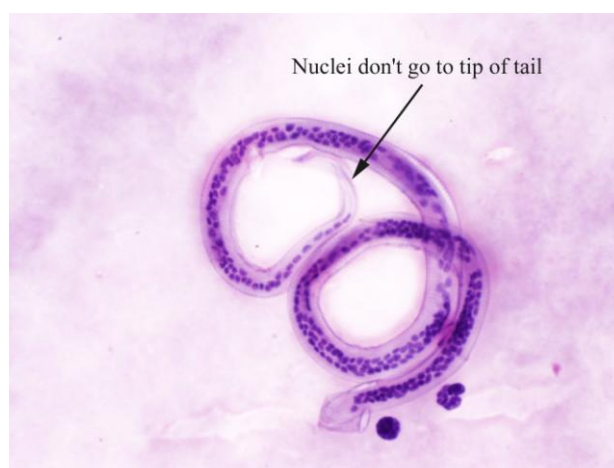

Fig.6: Shows *Wuchereria bancrofti* in thick smear

3.2 DEC provocative test (2mg/Kg)

After consuming Diethylcarbamazine (DEC), microfilariae enters into the peripheral blood in day time within 30-45 minutes and then it can be detected in peripheral blood.

3.3 Quantitative Blood Count (QBC)

QBC will identify the microfilariae and will help in studying the morphology. Though quick, it is not sensitive than blood smear examination.

4. CONCLUSION

Diagnosis of filariasis is made by demonstration of circulating microfilaria in the peripheral blood and in tissue sections of human. In case of very low number of microfilaria counts the concentration techniques are introduced and can detect the microfilaria parasite. A rapid test Binax Now® Filariasis Immunochromatographic Test (ICT) can detect the parasite within 10 minutes of test done. Now a days real time is also introduced for detection of filarial worms and it detects the parasites in case of very less count or no count in blood smear. Ultrasonography are introduced to detect the parasites.

REFERENCES

- [1] M. Jamail, K. Andrew, D. Junaidi, A. K. Krishnan, M. Faizal and N. Rahmah (2005), Field validation of sensitivity and specificity of rapid test for detection of *Brugia malayi* infection. *Tropical Medicine and International Health*, vol 10 (1), 99–104.
- [2] USAID's Neglected Tropical Disease Program: Target Diseases, Lymphatic Filariasis www.neglecteddiseases.gov/target_diseases/lymphatic_filariasis.
- [3] Freedman DO, de Almeida Filho PJ, Besh S, et al. Lymphoscintigraphic analysis of lymphatic abnormalities in symptomatic and asymptomatic human filariasis. *J Inf Dis* 1994; 170: 927-33.
- [4] Rath K. Nath, N. Mishra Shaloumy, Swain B.K., Mishra Suchismita and Babu, B.V. (2006) Knowledge and perceptions about lymphatic filariasis: a study during the programme to eliminate lymphatic filariasis in an urban community of Orissa, India. *Tropical Biomedicine* 23(2): 156–162.
- [5] Ramakrishna U. Rao, Gary J. Weil, Kerstin Fischer Taniawati Supali and Peter Fischer (2006), Detection of *Brugia* Parasite DNA in Human Blood by Real-Time PCR. *J. Clin. Microbiol.* 2006, 44(11):3887.
- [6] McCarthy J. (2000), Diagnosis of lymphatic filarial infection. In: *Lymphatic Filariasis*, ed. Nutman TB, Imperial College Press, London, 127-41.
- [7] Amaral F, Dreyer G, Figueredo-Silva J, et al (1994), Live adult worms detected by ultrasonography in human bancroftian filariasis. *Am J Trop Med Hyg*; 50: 735-57.
- [8] Shenoy RK, John A, Hameed S, et al (2000), Apparent failure of ultrasonography to detect adult worms of *Brugia malayi*. *Ann Trop Med Parasitol*; 94: 77-82.

- [9] Amaral F, Dreyer G, Figueredo JS, Norões J, Cavalcanti A, Samico SC, Santos A, Coutinho A (1994), Adult worms detected by ultrasonography in human bancroftian filariasis. *Am J Trop Med Hyg* 50: 753-757.
- [10] Noroes J, Addis D, Amaral F, Coutinho A, Medeiros Z, Dreyer G (1996), Occurrence of living adult *Wuchereria bancrofti* in scrotal area of men with microfilaremia. *Trans R Soc Trop Med Hyg* 90: 55-56.
- [11] www.filariasis.us/resources.html
- [12] Abraham Rocha I, Cynthia Braga I, Marcela Belém I, Arturo Carrera I, Ana Aguiar-Santos I et al (2009), Comparison of tests for the detection of circulating filarial antigen (Og4C3-ELISA and AD12-ICT) and ultrasound in diagnosis of lymphatic filariasis in individuals with microfilariae. *Mem. Inst. Oswaldo Cruz* vol.104 (4).
- [13] Lim PKC, Mak JW, Yong HS, Dhaliwal SS. (1984), Immunodiagnosis of Brugian filariasis: comparative efficiency of the indirect fluorescent antibody test and the enzymelinked immunosorbent assay. *Trop Biomed.* 1: 125-131.
- [14] Weil GJ, Lammie PJ, Weiss N. (1997), The ICT Filariasis Test: A Rapid-format Antigen Test for Diagnosis of Bancroftian Filariasis. *Parasitology Today*, 13(10):401-404.
- [15] Reddy GS, Das LK, Pani SP (2004), The preferential site of adult *Wuchereria bancrofti*: an ultrasound study of male asymptomatic microfilaria carriers in Pondicherry, India. *Natl Med J India*. 17(4):195-6.
- [16] I PCR assay for the detection of *Wuchereha bancrofti* infection in *Culex quinquefasciatus*. *Indian J Med Res.* 2001; 114: 59.
- [17] Hoti SL, Vasuki V, Lizotte MW, Patra KP, Ravi G, Vanamail P, Manonmani AM, Sabesan S, Krishnamoorthy K, Williams SA. Detection of *Brugia malayi* in laboratory and wild-caught *Mansonia* mosquitoes (Diptera: Culicidae) using Hha I PCR assay. *Bull Entomol Res* 2001; 91: 87.
- [18] Hoti SL, Patra KP, Vasuki V, Lizotte MW, Hariths VR, Sushma N, et al. Evaluation of a Ssp I PCR assay in the detection of *Wuchereria bancrofti* infection in the field collected *Culex quinquefasciatus* in the transmission studies of lymphatic filariasis. *J Applied Entomol* 2002; 126: 417-21.
- [19] Vasuki V, Patra KP, Hoti SL. A rapid and simplified method of DNA extraction for the detection of *Brugia malayi* infection in mosquitoes by PCR assay. *Acta Trop* , 2001;79: 245.
- [20] Shelley S, Manokaran G, Indirani M, Gokhale S, Anirudhan N. (2006), Lymphoscintigraphy as a diagnostic tool in patients with lymphedema of filarial origin--an Indian study. *Lymphology*, 39(2), 69-75.
- [21] Freedman DO, de Almeida Filho PJ, Besh S, Maia e Silva MC, Braga C. ea al (1994) Lymphoscintigraphic analysis of lymphatic abnormalities in symptomatic and asymptomatic human filariasis. *J Infect Dis.*170(4), 927-33.